



LED based occlusal and approx

F. Krause, D.J. Melner, R. St
Department of Operative Dentistry an

OBJECTIVE

The aim of the present *in vitro* study was to evaluate a novel LED based device for the detection of both occlusal and approximal carious lesions. Therefore, results should be compared to the histological caries extension.

MATERIAL AND METHODS

A total of eighty freshly extracted permanent premolars and molars were cleaned and stored in physiological saline solution. Specimens were divided into two groups of forty teeth each either for occlusal or approximal measurements. Teeth were set in blocks simulating the contact area. Caries diagnosis was performed using an LED device (D-Carie™, Nexs (Caries ID™, Dentsply), fig. 1a, b). The device is based on the ability to identify the characteristic spectral signature (absorption, reflection and diffraction) of carious tissue. Red light emitting diode (LED) radiation was transported to the occlusal or approximal area using the tip of the probe in contact with the occlusal surfaces (fig. 1c). Reflected light is converted into an electrical signal to be analysed. An audible signal differentiating three frequencies (low, moderate, fast) and the transition of the visual signal from green to red should identify the presence of caries. Digital bitewing radiographs were taken (fig. 2b, 3b). Subsequently, teeth were prepared for histological examination (fig. 2c, 3c). Teeth were fixed in formalin and embedded in a light-activated PMMA medium. Undecalcified ground sections of 50 µm were cut and stained with rhodamine B, acid fuchsin and light green. Slices were examined at 6 x magnification with a stereomicroscope. For statistical analysis, results of LED diagnosis and radiographic examination were compared to the histological caries extension (chi-square). With respect to the different readings of the LED system and the caries extension on the radiograph, the measure of association (lambda) for proportional error reduction with the dependant variable "histological caries extension" was calculated. Differences were considered as statistically significant at $p < 0.05$.




Figure 1: Caries detection system (D-Carie™-system, Caries ID™) (a) and probe of the measurement device (b). Both a visible and an audible signal suggest a carious lesion under the tooth surface (c)

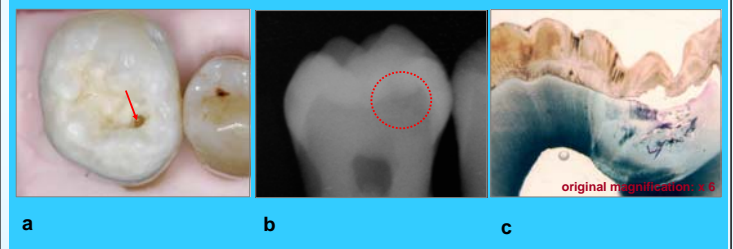


Figure 2: Representative example of a tooth showing an occlusal carious lesion (a), the respective radiograph (b) and the histological slice (c)

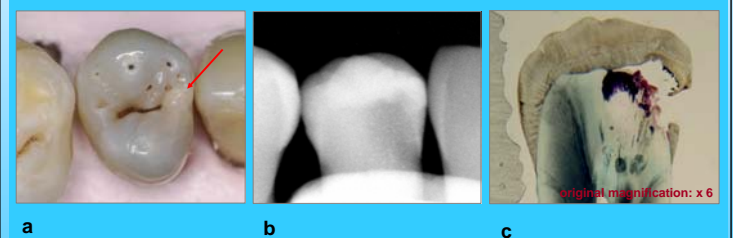


Figure 3: Representative example of a tooth showing an approximal carious lesion (a), the respective radiograph (b) and the histological slice (c)



awirej, S. Jepsen, A. Braun
d Periodontology, University of Bonn

RESULTS

Signal frequency of the LED device and caries extension on bitewing radiographs were dependent on the histologically assessed caries decay ($p < 0.05$, chi-square) for both occlusal (fig. 4) and approximal caries (fig. 5). A higher measure of association could be found between clinical carious extent and LED diagnosis in occlusal lesions ($\lambda=0.704$, tab. 1) than for approximal lesions ($\lambda=0.565$, tab. 2). Sensitivity of radiographic assessment in occlusal lesions (75.9%) was lower than the value for LED evaluation (100%) with comparable values for specificity (tab. 1). Sensitivity and specificity for both radiographic diagnosis and LED assessment were comparable for approximal lesions (tab. 2).

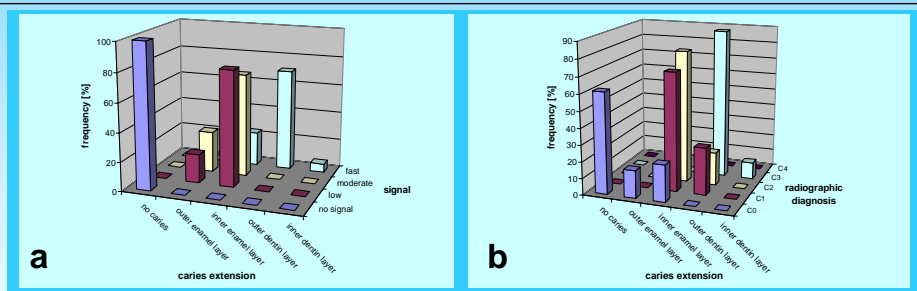


Figure 4. Occlusal caries detection. Signal frequency of the LED based caries detection device depending on the histological caries extension (a). Radiographic diagnosis depending on the histologically assessed caries extension (b)

| | LED system | Radiographic diagnosis |
|-------------|------------|------------------------|
| sensitivity | 100 | 75.9 |
| specificity | 100 | 100 |
| lambda | 0.704 | 0.593 |

Tab. 1. Sensitivity, specificity and lambda for occlusal caries detection using the LED based caries detection device and bitewing radiographs

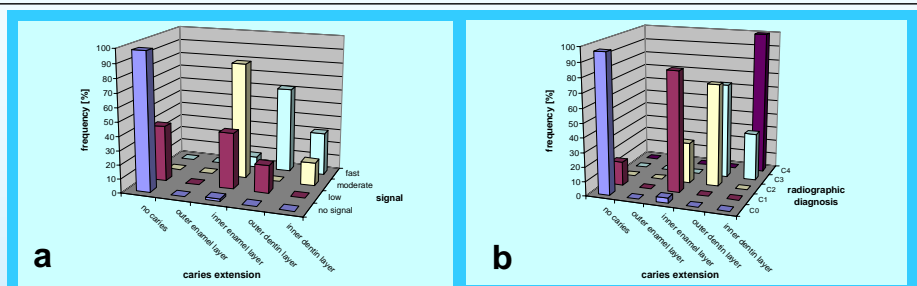


Figure 5. Approximal caries detection. Signal frequency of the LED based caries detection device depending on the histological caries extension (a). Radiographic diagnosis depending on the histologically assessed caries extension (b)

| | LED system | Radiographic diagnosis |
|-------------|------------|------------------------|
| sensitivity | 95.7 | 91.3 |
| specificity | 96.5 | 98.2 |
| lambda | 0.565 | 0.696 |

Tab. 2. Sensitivity, specificity and lambda for approximal caries detection using the LED based caries detection device and bitewing radiographs

CONCLUSION

Occlusal caries diagnosis can be improved by LED diagnosis compared to radiographic assessment. With respect to approximal lesions, carious decay is detectable with the probe positioned on the marginal ridge of the occlusal surface. However, further *in vitro* and *in vivo* studies have to evaluate the possibility of reducing or even replacing radiographic examinations.

Priv.-Doz. Dr. Felix Krause, DDS, PhD
 Department of Operative Dentistry
 and Periodontology
 University Hospital Bonn
 Welschnonnenstr. 17
 53111 Bonn, Germany
 Email: felix.krause@uni-bonn.de

